

What chest auscultation can add in an age of advanced diagnostics

Quantitative computed tomography, functional imaging, forced oscillation technique (FOT) and fractional exhaled nitric oxide have expanded our understanding of respiratory disease. There is much to be excited about. Yet I wonder whether our enthusiasm for investigations has taken us a little too far from the bedside.

Chest examination remains quick, personal and immediately available. It creates a moment of focused attention with the patient and can sharpen a working diagnosis before investigation results return. Sometimes, it provides the clue that makes us reconsider a diagnosis we thought was settled.

Its limitations matter. A normal examination does not exclude significant disease, and an abnormal sound rarely establishes a diagnosis by itself. But listening carefully still has something to offer.

1. The inspiratory squeak: a clue that spirometry can miss

A brief, high-pitched squeak during inspiration—sometimes called a squawk—is easily overlooked or recorded simply as “wheeze”. Yet it can be an important clue to small-airway involvement.

We may hear it in asthma affecting the small airways, hypersensitivity pneumonitis, and other interstitial lung diseases with bronchiolar involvement. It is a clue, not a disease-specific sign.

Spirometry can be normal despite small-airway disease. A reassuring result should not dismiss a reproducible abnormal sound or otherwise unexplained respiratory symptoms.



Open bronchiole Narrowed bronchiole

The practical point: consider small-airway involvement when you hear an inspiratory squeak, even if spirometry is normal. Further testing, such as FOT, may be appropriate if clinically indicated.

2. Wheeze: listen to its character and distribution

“Wheeze present” leaves out useful information.
A widespread, polyphonic expiratory wheeze suggests diffuse airway narrowing and is compatible with asthma, although it is not specific to asthma. A persistent focal or monophonic wheeze should raise a different question: could there be localised airway obstruction?

Normal spirometry does not settle the matter. Asthma can have normal lung function between episodes, and a normal result should not automatically close the diagnostic enquiry when the clinical picture remains suggestive.



Diffuse Focal

The practical point: reconsider both the diagnosis and the next investigation when the sound, symptoms and spirometry do not fit together.

3. The “wheeze” that comes from the upper airway

A loud respiratory sound is not necessarily bronchial wheeze.

An inspiratory sound that is prominent over the neck, especially with throat tightness or voice change, should prompt consideration of inducible laryngeal obstruction, previously often called vocal cord dysfunction. It can mimic asthma and may coexist with it. Confirmation requires appropriate laryngeal assessment, ideally during symptoms or provocation.

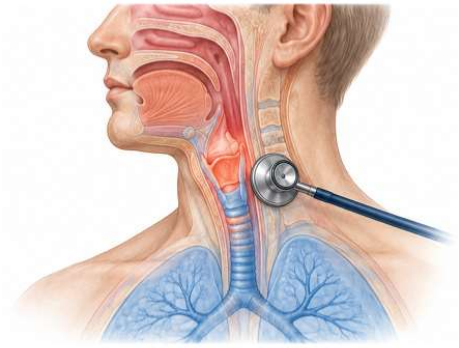

The practical point: listen over the neck as well as the chest before escalating asthma treatment for an atypical “wheeze”. New or persistent stridor also requires consideration of structural upper-airway obstruction.

4. Bronchial breathing: a clue to underlying consolidation

Harsh, tubular breathing heard over the peripheral lung fields, with a prominent expiratory component, should draw attention to that region.

In the appropriate clinical setting, bronchial breathing supports consolidation. It does not establish that the cause is bacterial pneumonia, but it can strengthen the working diagnosis and help direct imaging.

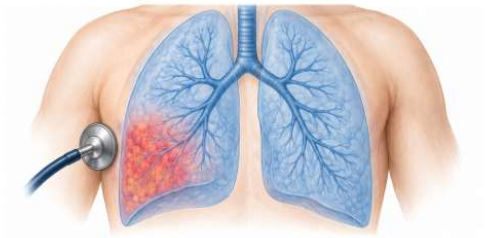

The practical point: document where the finding is heard and interpret it alongside the history, vital signs and other examination findings.

5. When the crackles disappear, check what has replaced them

Serial examination can be particularly valuable in pneumonia. If previously audible crackles are replaced by markedly reduced or absent breath sounds over the same region, do not assume the chest is improving—especially if fever, pleuritic pain or breathlessness persists. An evolving pleural effusion is one possibility. In a patient with pneumonia, this raises concern for a parapneumonic effusion, which may be complicated by pleural infection. Auscultation cannot distinguish a simple effusion from empyema; imaging and, when indicated, pleural fluid assessment are needed.

The practical point: a quieter chest in a patient who is not improving warrants prompt reassessment and imaging, with urgent hospital assessment if clinically deteriorating.



The practical point: a quieter chest in a patient who is not improving warrants prompt reassessment and imaging, with urgent hospital assessment if clinically deteriorating.

.

Bring the examination back into the diagnostic conversation

We do not need to overstate the stethoscope's accuracy to recognise its value. The useful habit is to describe what we hear: inspiratory or expiratory, focal or diffuse, single-pitched or polyphonic—and whether it has changed. Those details can refine a differential diagnosis, challenge an existing label and guide the next investigation.

A useful examination helps us ask a better diagnostic question.

WRS For GP, Evidence Insight Precision, Western Respiratory Sleep, Joondalup, WA 6027, Australia

Unsubscribe Manage preferences