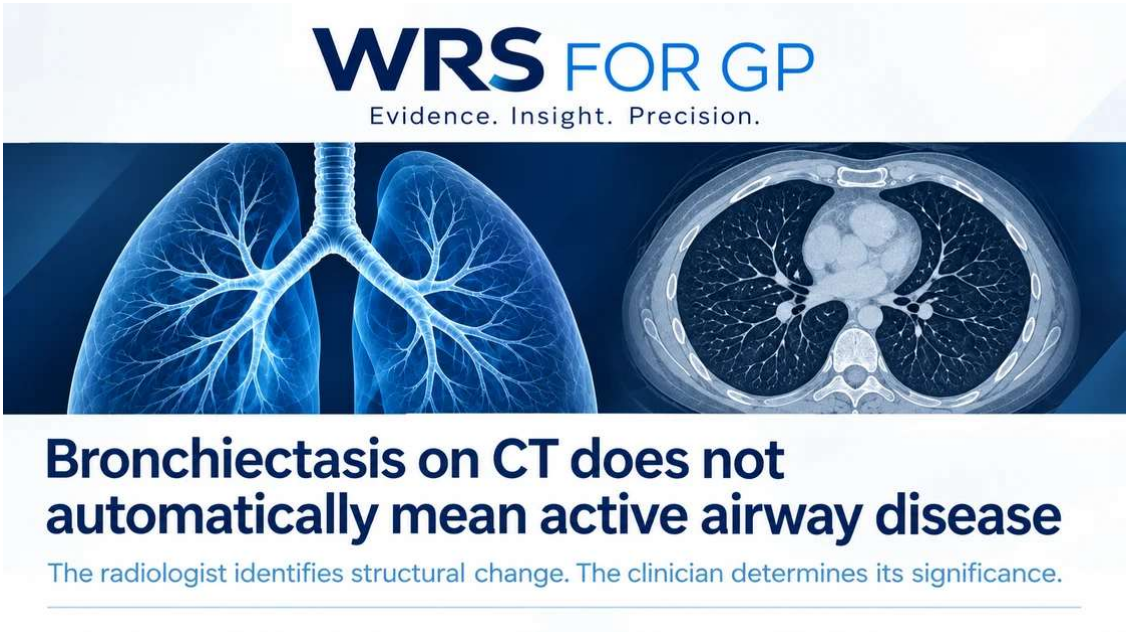

A radiological diagnosis of bronchiectasis describes airway dilation. By itself, it does not establish active inflammation, infection or the cause of a patients cough.

An older patient has a computed tomography (CT) scan for chronic cough. The report mentions “mild bilateral lower-lobe bronchiectasis”.
Now the cough appears to have an explanation. The patient has a diagnosis. The search can stop.

Or can it?

The scan may have identified a structural finding with little relevance to the presenting symptom. An incidental finding can occur in a symptomatic patient.

Quick Take

- **Structure is not activity:** airway dilatation alone does not establish active airway disease.
- **Presence is not causation:** bronchiectasis may coexist with a cough caused by something else.
- **Context determines significance:** assess accompanying airway changes and the respiratory history before deciding on treatment.

When a measurement becomes a diagnosis

One radiological feature of bronchiectasis is an airway that is wider than its accompanying pulmonary artery. Other features include loss of normal tapering and visibility of airways unusually close to the pleura.

Yet the airway-to-artery ratio is influenced by age. Research in asymptomatic adults has shown that ratios in older people can overlap with those used to identify bronchiectasis. A measurement can cross a diagnostic threshold without telling us how much that finding matters to the patient.

The radiologist is correct to describe the structural appearance. It is the clinician's role to make sense of it.

The pattern that makes me pause

In practice, I see older patients with mild bronchial dilatation in both lower lobes, barely meeting radiological criteria. The airway walls appear normal. There are no visible endobronchial secretions.
Some are asymptomatic. Others have chronic cough, but further assessment identifies another cause.

This is an observation from my practice, not a validated "benign" pattern. Neither age nor bilateral lower-lobe distribution guarantees that a finding is inconsequential. What makes me pause is the mismatch: a cough that needs explaining, but relatively little accompanying evidence that the dilated airways are responsible.

Does the rest of the picture support the label?

Airway calibre describes structure. Bronchial wall thickening, retained secretions, mucus plugging and associated small-airway changes provide further clues about what may be happening within those airways. Their extent and distribution also matter.

These are clues, rather than a definitive test of “activity”. Wall thickening may reflect chronic change; mucus plugging does not by itself prove infection. Their absence does not exclude clinically important disease.

That is why the history remains essential. Is there daily sputum? Recurrent chest infections? Haemoptysis? Episodes of respiratory deterioration?

A patient with regular purulent sputum and repeated infections presents a different clinical picture from someone with a dry cough and none of those features, even if both reports use the words “mild bronchiectasis”.

What would you investigate if the scan had not mentioned bronchiectasis?

Would you still consider asthma or eosinophilic airway disease? Upper-airway disease? A medication-related cough? Reflux, where the history supports it?
Those possibilities do not disappear because the scan contains an abnormality. Several contributors may also coexist.
A dry cough does not rule out bronchiectasis as a contributor. It should, however, make us examine the connection rather than assume it.
The trap is premature closure: the finding is visible, the explanation is plausible, and the remaining possibilities receive less attention.

Give the patient an interpretation

“Your scan shows some mild widening of the airways, which the radiologist has called bronchiectasis. That finding is real, but it may not explain your cough. We need to consider the other possible causes and decide whether these airway changes need any specific care.”

This acknowledges the finding without assigning it more significance than the evidence supports.

Treatment should follow the clinical assessment. The radiological label alone is not an indication for antibiotics. Persistent sputum, recurrent infections, haemoptysis, deterioration or concerning imaging features warrant further evaluation.

The radiologist can be correct about bronchiectasis while we are wrong to attribute the cough to it.

Dr Cheng Long Lu | Respiratory & Sleep Physician

WRS FOR GP

Evidence. Insight. Precision.

WRS For GP, Evidence Insight Precision, Western Respiratory Sleep, Joondalup, WA 6027, Australia

Unsubscribe Manage preferences